

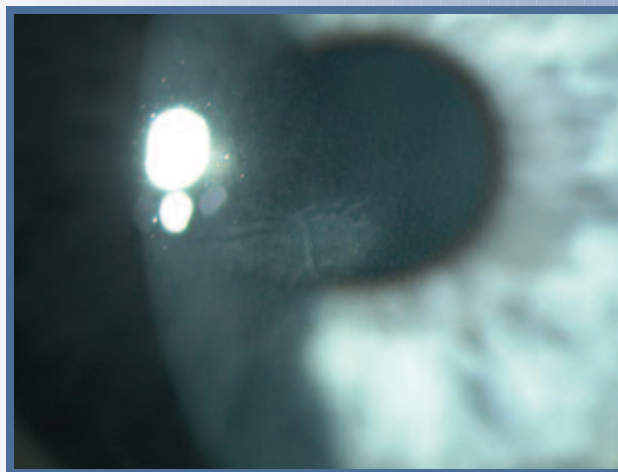
# MALONEY VISION INSTITUTE

# CLINICAL UPDATE

## CENTRAL TOXIC KERATOPATHY

### INTRODUCTION

A 47 year old male consulted with us for LASIK. His preoperative refraction was -2.75 -1.50 x 098 OD and -2.50 -1.75 x 065. Both eyes corrected to 20/15. He underwent uneventful LASIK surgery in both eyes. His binocular vision was 20/25-1 on post-op day 1. Moderate DLK OU was present. His fluoromethalone eye drops were increased from q.i.d. to every hour for two days. He presented on postoperative day 6 with blurry vision in both eyes. Uncorrected vision was 20/30 OD and 20/25 OS. He had a central area of haze in each cornea, extending posteriorly from the flap interface with marked striae and thinning of the bed in both eyes (*Figure 1*). A diagnosis of central toxic keratopathy was made. He developed significant hyperopia in each eye. Over the next twelve months his corneas cleared and the hyperopia largely resolved (*Table 1*). He underwent LASIK enhancement one year postoperatively without recurrence of the opacities. Uncorrected acuity after enhancement was 20/15 OU.



**Figure 1:**

Central toxic keratopathy. The patient presented on postoperative day 3 with an area of paracentral corneal haze with flap striae in the left eye. No inflammation was present. The area of stromal haze was posterior to the flap interface.

**TABLE 1: EVOLUTION OF REFRACTION AND BEST CORRECTED VISUAL ACUITY**

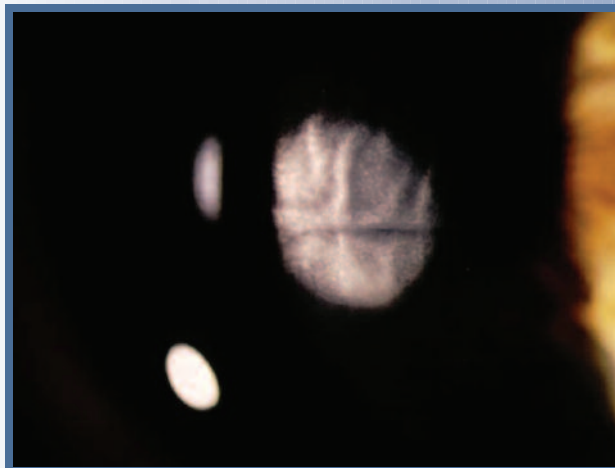Time post initial surgery	Refraction OD	Refraction OS
8 days	+ 4.50 – 3.00 x 124 20/30	+ 8.00 – 1.50 x 101 20/30
11 days	+ 3.25 – 2.00 x 138 20/40	+ 4.50 – 1.50 x 124 20/40
2.5 weeks	+ 2.00 – 3.75 x 137 20/25	+ 3.50 – 0.75 x 010 20/25
5 weeks	+ 1.25 – 1.50 x 146 20/15	+ 1.25 – 1.00 x 027 20/15-
4 months	+ 0.50 – 1.25 x 146 20/15	+ 1.25 – 0.75 x 025 20/15
7 months	+ 0.75 – 1.75 x 152 20/15	+ 1.50 – 1.25 x 020 20/15
13 months	+ 0.50 – 1.50 x 152 20/15	+ 1.00 – 0.75 x 025 20/15
13 months	LASIK Enhancement	LASIK Enhancement
14 months	20/15 Uncorrected	20/15 Uncorrected

## DISCUSSION

Central toxic keratopathy (CTK) is characterized by a focal white lesion of the central cornea that extends from the interface anteriorly into the flap or posteriorly into the bed (*Figure 2*). It develops on postoperative day 2 to 4. It is usually associated with DLK and presents several days after the onset of DLK. Because of the coexistence of DLK, it can be mistaken for a corneal ulcer, but is differentiated by the absence of an epithelial defect and the absence of inflammatory cells in the whitish lesion. The DLK clears in a few days but the noninflammatory white lesion persists, associated with clear striae. There is central stromal tissue loss, resulting in a significant hyperopic shift. Over time the hyperopia resolves and the lesion clears. Topical corticosteroids are not useful, and potentially harmful because of the risk of cataract and increased intraocular pressure. If there is a residual refractive error after the lesion clears, an enhancement can be done.

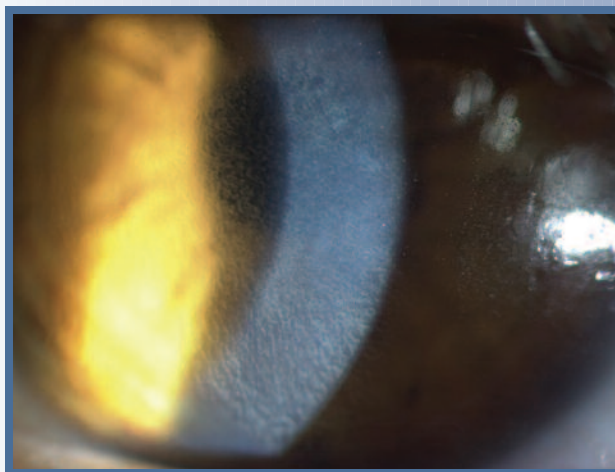
Central toxic keratopathy is often called "stage 4 DLK", but we believe this term is a misnomer. CTK is distinguished from DLK (*Figure 3*) by the absence of inflammation, focal involvement of only the central cornea, and the extension of the opacity posterior or anterior to the interface.

We believe that CTK represents apoptosis of keratocytes as a toxic response to something that occurs during surgery. Its cause is unknown. It is important to note that central toxic keratopathy can occur after PRK or LASEK, in the absence of a flap.



**Figure 2:**

Central Toxic Keratopathy. This is a typical presentation in a different patient several days after a LASIK procedure. There is central opacification which extends posterior to the bed, with obvious flap striae. There is no inflammation.



**Figure 3:**

Diffuse Lamellar Keratitis (DLK). This is a typical presentation in a different patient on postoperative day 2 after a LASIK procedure. Note the diffuse infiltration of inflammatory cells, confined to the flap interface.

---

## MALONEY VISION INSTITUTE

If you have questions or need further information, please contact Dr. Robert Maloney at [rm@maloneyvision.com](mailto:rm@maloneyvision.com) or Dr. Farid Eghbali at [dregbali@maloneyvision.com](mailto:dregbali@maloneyvision.com). You can also call us at (310) 208-3937 or send a fax to (310) 208-0169.